Airway Obstructed by Foreign Material: The Heimlich Maneuver

Charles Wayne Guildner, MD
Doug Williams, ARRT
Tom Subitch, MD
Everett, Washington

To investigate the application of a cough-creating thrust for the removal of airway-obstructing foreign material, the thrust was applied to six adult male anesthetized volunteers at the waist, at the low chest level, and at the midchest level, with the subjects in both the horizontal-lateral and the sitting positions. Air volume, peak air flow rate, and airway measurements were made. Both the low chest and midchest thrusts produced significantly better results than did the abdominal thrust. There were no side effects attributable to the thrusts. The ease of application and consistently better level of results indicate that the chest thrust is the technique of choice. The application of the chest thrust should be integrated into the concepts of basic life-support and cardiopulmonary resuscitation.

Guildner CW, Williams D, Subitch T: Airway obstructed by foreign material: the Heimlich maneuver. *JACEP* **5**:675-677, September 1976. *airway, obstructed; Heimlich maneuver; cardiopulmonary resuscitation; life-support.*

INTRODUCTION

The Heimlich maneuver, described by Henry Heimlich, MD, in the June, 1974 issue of *Emergency Medicine*, has received wide attention in the news media as a means to relieve airway obstruction caused by choking on a piece of meat or other foreign material. The maneuver is performed by positioning yourself behind the victim and encircling his waist with your arms. The thumb side of your fist is placed against the patient's abdomen just above the navel and below the rib cage. The fist is grasped with your other hand and pressed into the patient's abdomen with a quick upward thrust. The procedure may be repeated.

METHOD

Six adult male volunteers, having given written, detailed, informed consent, were anesthetized with methohexital, intravenously, plus halothane, nitrous oxide, oxygen and succinyl choline prior to intubation. The succinyl choline was administered in a slow intravenous drip thus avoiding fasciculations.

An 8.5 mm sterile, plastic, low pressure-cuffed endotracheal tube was placed using direct laryngoscopy. The cuff was inflated sufficiently to prevent air leak during positive pressure ventilation. Succinyl choline was discontinued, spontaneous ventilation returned, and anesthesia maintained with 0.5% to 1% halothane.

During each application of the thrust, total airflow and peak flow rate were measured in each subject. Airway pressure curve recordings measured at the endotracheal tube were made with four of the subjects.

Total volume and peak flow rate were measured simultaneously with a Monghan M403 pulmonary function analyzer. A one-way valve was incorporated into the system so that only expired flows were measured. The analyzer was calibrated in line with a Collins 13.5 liter water spirometer before the studies were done.

Airway pressure measurements were made with an IR-4 Electronics for Medicine pressure recorder and an Altech MS10 pressure transducer. The equipment was calibrated prior to each thrust. A permanent printout was obtained for each recording (Figure). The transducer was inserted in the endotracheal tube so that it totally occluded the orifice.

The subjects were hyperventilated to the point of controlled respirations, so that no spontaneous respiratory effort would be recorded,

From the Providence Hospital, Everett, Washington.

Supported in part by Providence Hospital, Everett, Washington.

Address for reprints: Charles W. Guildner, MD, Medical Anesthesia Associates, Inc, 631 Medical Dental Building, Everett, Washington 98202.

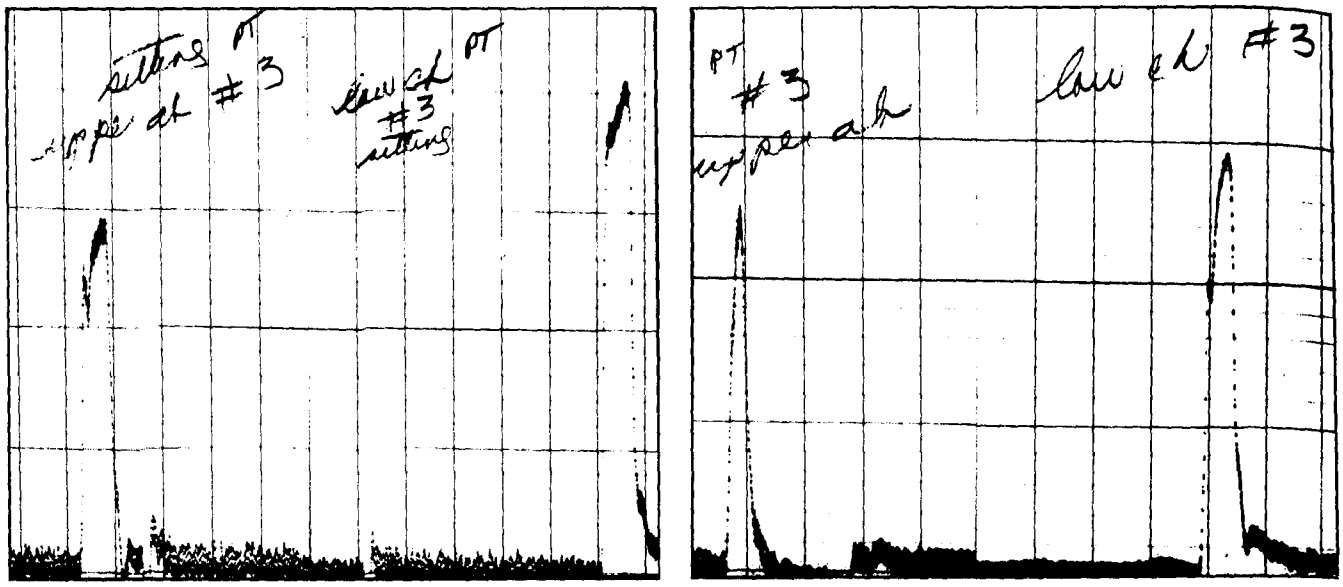

Fig. *Sample peak pressure tracings.* (left) *Abdominal and chest thrusts applied to subject in sitting position.* (right) *Abdominal and chest thrusts applied to subject in horizontal position.*

and allowed to reach a resting expiration (functional residual capacity) prior to each determination.

The maneuver was applied at two locations other than the abdomen — the low chest and midchest. For the low chest position, the rescuer is behind the subject, locates the xiphoid and grasps his fist two or three finger breadths above the xiphoid over the sternum. For the midchest position, the rescuer is behind the subject, grasps his fist at the nipple line over the sternum. For the Heimlich or abdominal position, the rescuer is behind the subject, grasps his fist at the waist or just above the belt line and thrusts up toward the diaphragm.

The thrust methods were applied at all three levels with the subject in the horizontal-lateral position and then repeated with the subject in the sitting position, leaning forward.

Four or five rescuers applied the maneuvers on each of the six subjects. The rescuers included four men weighing between 170 lb and 210 lb, one woman weighing 110 lb, and one 13-year-old boy weighing 95 lb. The subjects' weights ranged between 175 and 220 lb.

Every effort was made to have each rescuer apply the maneuver with the same vigorous, hard thrust at each of the three levels of application.

The technique of delivering a "sharp blow between the shoulder blades" was also applied several times. This procedure was so ineffectual in creating airflow or increased pressure within the chest, it was abandoned.

RESULTS

The recordings of airflow volume, peak flowrate and pressure are listed in the Table.

Each volunteer was interviewed 90 minutes after the end of the procedure and again the next day. Each was asked to report any aching, soreness, pain, or discomfort. All reported a sore throat lasting from 24 to 72 hours, most likely due to irritation from the endotracheal tube. None indicated any discomfort of the chest or abdomen nor has had any adverse effects from the procedures.

DISCUSSION

The low and midchest thrusts produced better results than did the abdominal thrust. The midchest thrust produced slightly better results with

Table
AIRFLOW VOLUME, PEAK FLOWRATE AND PRESSURE FOR EACH POSITION

	FVC-liter	(Range)	PF-liter min	(Range)	Peak Pressure mm HG	(Range)
Horizontal						
abdomen	.29	.08-.74	55	36-98	17	10-30
low chest	.35	.10-.87	68	33-105	25	20-32
midchest	.23	.08-.54	60	38-83	19	18-21
Sitting						
abdomen	.38	.08-.92	65	24-97	19	10-29
low chest	.52	.17-1.03	94	53-148	32	20-44
midchest	.44	.18-.84	99	54-154	34	26-42

the subject in a sitting position than did the low chest thrust, while the latter was more easily and quickly applied and produced better results with the subject horizontal. The data on airflow and pressures, which indicated the chest thrusts resulted in greater airflow and pressures than the abdominal thrust, suggests that the chest thrusts should be the more effective method.

The lack of side effects attributable to the thrust and the relative safety of the procedure were impressive.

CONCLUSION

We feel the emergency management of an obstructed airway due to foreign material should not be thought of as an isolated technique but rather should be integrated into the basic life-support concepts of cardiopulmonary resuscitation.[1] Also, there should be separate procedures for the conscious and unconscious victims of airway obstruction. We recommend the following:

Conscious victim with airway obstruction. This person, who usually has been eating or has a foreign body in his mouth, suddenly cannot speak, cough, or breathe. Prompt action is indicated, preferably while the victim is still conscious. He should not be left alone. When complete airway obstruction is recognized, the following sequence should be applied with the victim sitting or standing:

1) Back blows — four in rapid succession; if ineffective —

2) Abdominal or chest thrust — repeat until effective or until victim becomes unconscious.

Unconscious victim with airway obstruction. Sudden collapse and loss of consciousness requires immediate attention. Even when someone has been eating, this emergency may be due to stroke, fainting, heart attack or respiratory depression from some other cause, as well as to anoxia from foreign body obstruction of the airway.[2]

Whatever the cause, the first priority is to assure an open airway and provide artificial ventilation if necessary. If the patient is not breathing but can be ventilated, artificial ventilation should be instituted. If there is no pulse, cardiopulmonary resuscitation, including closed chest heart compression, should be initiated. If attempts to ventilate indicate foreign body obstruction, attention should immediately be directed to the additional manual maneuvers in the following sequence:

1) Ventilate (mouth-to-mouth). If unable to ventilate —

2) Back blows (four in rapid succession). If ineffective —

3) Abdominal or chest thrusts (four). If ineffective —

4) Finger probes (if jaw relaxed). If unsuccessful —

5) Repeat sequence of

a) Ventilate

b) Back blows

c) Abdominal or chest thrusts

d) Finger probes.

6) Persist.

REFERENCES

1. Standards for Cardiopulmonary Resuscitation (CPR) and Emergency Cardiac Care (ECC). Report from the National Conference on Standards for Cardiopulmonary Resuscitation (CPR) and Emergency Cardiac Care (ECC). *JAMA* **227** (suppl):837-868, 1974.

2. Foreign body obstruction of the airway. American National Red Cross First Aid Manual. 1976, p 4.

Correction: An error appeared in Table 2 of "Approach to Acid-Base Problems in the Critically Ill and Injured" by Wilson and Sibbald published in the July 1976 issue of *JACEP*. The Table with the corrected portion in bold face type appears below, in the right-hand column (alkalosis).

Table 2
ACID-BASE ABNORMALITIES AS DEFINED BY THE pCO_2 AND BICARBONATE LEVELS

pCO_2 (mm Hg)	Bicarbonate (mEq/liter)		
	< 21	21 — 26	> 26
> 45	Combined metabolic & respiratory acidosis	Respiratory acidosis	Metabolic alkalosis & respiratory acidosis
35 — 45	Metabolic acidosis	Normal	Metabolic **alkalosis**
< 35	Metabolic acidosis & respiratory alkalosis	Respiratory alkalosis	Combined metabolic & respiratory alkalosis

ELSEVIER

Resuscitation 44 (2000) 105–108

RESUSCITATION

www.elsevier.com/locate/resuscitation

Airway pressure with chest compressions versus Heimlich manoeuvre in recently dead adults with complete airway obstruction

A. Langhelle [a,b,*], K. Sunde [a,b], L. Wik [c], P.A. Steen [d]

[a] Norwegian Air Ambulance, Department of Research and Education in Acute Medicine, N-1441 Droebak, Norway
[b] Institute for Experimental Medical Research, Ullevaal University Hospital N-04047 Oslo, Norway
[c] Medinnova SF, National Hospital of Norway, N-0027 Oslo, Norway
[d] Departments of Anaesthesiology and Emergency Medical Services, Ullevaal University Hospital, N-0407 Oslo, Norway

Accepted 22 November 1999

Abstract

In a previous case report a standard chest compression successfully removed a foreign body from the airway after the Heimlich manoeuvre had failed. Based on this case, standard chest compressions and Heimlich manoeuvres were performed by emergency physicians on 12 unselected cadavers with a simulated complete airway obstruction in a randomised crossover design. The mean peak airway pressure was significantly lower with abdominal thrusts compared to chest compressions, 26.4 ± 19.8 cmH_2O versus 40.8 ± 16.4 cmH_2O, respectively ($P = 0.005$, 95% confidence interval for the mean difference 5.3–23.4 cmH_2O). Standard chest compressions therefore have the potential of being more effective than the Heimlich manoeuvre for the management of complete airway obstruction by a foreign body in an unconscious patient. Removal of the Heimlich manoeuvre from the resuscitation algorithm for unconscious patients with suspected airway obstruction will also simplify training. © 2000 Elsevier Science Ireland Ltd. All rights reserved.

Keywords: Airway obstruction; Basic Life Support (BLS); Cardiopulmonary resuscitation (CPR); Chest compression; Education; Guidelines

1. Introduction

Foreign body airway obstruction is an uncommon but preventable cause of cardiac arrest, with an incidence of 0.65–0.9/100.000 [1,2] as a cause of death. In choking victims who stop breathing the European Resuscitation Council (ERC) recommends up to five sharp slaps between the shoulder blades, followed by abdominal thrusts (the Heimlich manoeuvre) if this fails. If the victim becomes unconscious, this is to be followed by 'the sequence of life support' [3]. The American Heart Association (AHA) recommends the Heimlich manoeuvre with alternating finger sweeps as the only technique [4], arguing that back blows may not be as effective as Heimlich manoeuvre in adults [5,6]. The AHA also claims that this will simplify training [4].

Based on a single case report Skulberg [7] suggested that standard chest compressions could be a better technique. If this is true, two additional goals might be achieved. It would simplify what needs to be learned for CPR and reduce the time without circulation from chest compressions in patients with cardiac arrest. We have therefore conducted a study of the airway pressure generated by chest compressions compared to abdominal thrusts in recently dead patients. Human cadavers were selected instead of animals, as the shape of the chest is different between animals and humans which makes extrapolation of data from one to the other unreliable.

* Corresponding author. Tel.: +47-23016819; fax: +47-23016799.
E-mail address: audun.langhelle@ioks.uio.no (A. Langhelle)

PII: S0300-9572(00)00161-1

2. Materials and methods

The study was approved by the Regional Committee for Medical Research Ethics and performed in the Emergency Medical Service System of Oslo. Cadavers are not covered by the Helsinki declaration, and the ethics committee did not require informed consent from relatives. Twelve unselected recently dead adults of either sex were studied immediately after unsuccessful resuscitation from prehosptial cardiac arrest. While still intubated and with the cuff inflated to create an airtight seal, the tracheal tube (ID 8.0 mm) was connected to a handheld pneumotachograph (VentCheck™, model 101, Novametrix Medical Systems, CT, USA) for airway pressure measurements. The proximal end of the sensor was plugged to stimulate complete airway obstruction.

The peak pressures achieved with five standard chest compressions were compared with peak pressures achieved with five abdominal thrusts (Heimlich manoeuvre) in a randomised, crossover design. Before starting each procedure it was ensured that the lungs were in the resting expiratory position. Four male emergency physicians weighing 80–90 kg performed the procedures. All were advanced life support instructors with many years of practical CPR experience. Both procedures were performed according to the European Resuscitation Council guidelines [3]. The abdominal thrusts were given kneeling astride the supine cadaver. Two paramedics controlled the performance of the procedures and recorded the results. The physicians received no feedback and were blinded from the results. Patient sex, age, particulars about their size/shape and complications during CPR such as rib fractures or lung aspiration were recorded.

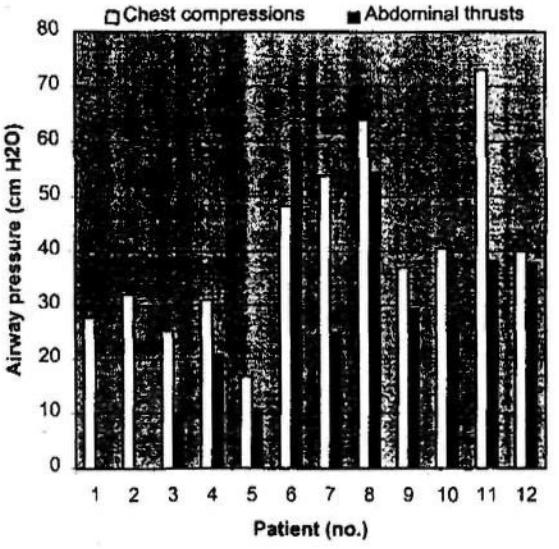

Fig. 1. Airway pressures with chest compressions and abdominal thrusts on twelve recently dead adults with complete airway obstruction. The airway pressure is significantly lower with abdominal thrusts than chest compressions ($P = 0.005$).

The mean pressures generated by the five chest compressions were compared to the mean pressures generated by the five abdominal thrusts using Jandel SigmaStat© statistical software (Erkrath, Germany). Each cadaver served as its own control. After assessing the distribution of the data distribution, a paired t-test was used. Data are presented as means $\pm$ SD.

3. Results

Ten recently dead men and two women with a mean age of 68 ± 15 years and mean body weight of 80 ± 15 kg were studied. Rib fractures were noted in three patients and pulmonary aspiration in one during the preceding resuscitation. One patient was very thin and the physician noted that he felt very little resistance in the epigastric region during abdominal thrusts before he felt the vertebral column. One corpse was extremely obese with a potbelly.

The mean peak airway pressure was significantly lower during abdominal thrusts compared to chest compressions, 26.4 ± 19.8 cmH_2O versus 40.8 ± 16.4 cmH_2O ($P = 0.005$, 95% confidence interval for the mean difference 5.3–23.4 cmH_2O) (Fig. 1). In all but one cadaver, the extremely obese subject, the mean airway pressure was higher with chest compressions compared to abdominal thrusts. In two cadavers, the very thin subject, and an 80 kg woman with pulmonary aspiration, there was no detectable airway pressure change at all with abdominal thrusts (patients 1 and 2, Fig. 1)

4. Discussion

In this study we achieved higher airway pressures with standard CPR chest compressions than with abdominal thrusts in recently dead subjects with complete airway obstruction.

Since the introduction of abdominal thrusts by Heimlich in 1974 [6] there has been debate and controversy regarding which manual rescue technique is most efficient in choking victims. Most studies have compared abdominal thrusts, various chest thrusts and back blows [5,8–10]. For unconscious patients the suggested technique has been the Heimlich manoeuvre with rescuer sitting astride the patient. In the unconscious, markedly obese victim the AHA advocates chest thrusts (the hand position being identical to that for chest compressions) as an option. This is in contrast to our findings, where the noticeably corpulent subject was the only one where abdominal thrusts generated a higher airway pressure. In 1992 Skulberg [7] suggested that chest compressions might be more effective than the Heimlich manoeuvre in the unconscious subject. This was based on a case where the Heimlich manoeuvre failed to dislodge a foreign body in an unconscious patient. As the patient also was pulseless, CPR was then started, and the airway was cleared with the first chest compression. The present study confirms Skulberg's hypothesis. We are aware of only one study of standard CPR chest compressions for foreign body removal. Gordon et al. [8] compared chest compressions with the Heimlich manoeuvre in six adult, anaesthetised volunteers and found pressures in the same range for the two methods (23 versus 17 cmH_2O, respectively). Their findings have, to our knowledge, never been published in a peer-reviewed journal and there is no specific description of the way they performed the chest compression other than 'standard external compression'. It is not known if chest compressions were done according to the current recommended guidelines. It would not be ethical to do 4–5 cm compression of the sternum in healthy volunteers because of the significant risk of causing damage such as rib fractures, and the pressures achieved by Gordon et al. were lower with both techniques than in the present study.

In 1978, Ruben et al. [10] compared the Heimlich manoeuvre with sternal thrusts on six cadavers and found higher pressure with the latter, median 18 (range 0–62) versus 30 (range 16–40) cmH_2O, respectively.

It has been speculated that the removal of a foreign body is dependent both on the pressure required to dislodge it and the ability to maintain pressure and potential air flow over time [8,11]. Thus, while a precordial thump might give a high peak pressure, it is sustained for only a very brief period with low flow rates [8]. The pressure is applied for a longer time with chest compressions. In the study by Gordon et al. [8] the airflows both with a partial airway obstruction and an open airway were similar for the Heimlich manoeuvre and chest compressions.

Substituting chest compressions for the Heimlich manoeuvre in unconscious patients has potential advantages in addition to creating a higher airway pressure. It will remove one step in managing an unconscious patient with cardiac arrest. The patient will be treated identically whether or not there is a foreign body airway obstruction. This should reduce confusion and improve training and practical performance. There is much evidence in the literature that the learning and retention of CPR skills is not very efficient [12–14]. There are many psychomotor skills to achieve, and there has been a drive towards simplifying CPR in the hope that this will reduce rescuer confusion and improve performance [15]. If removal of a foreign body can be achieved by chest compressions, this will also reduce the time without circulation in the patient with cardiac arrest.

In conclusion, the present findings indicate that standard chest compressions are more effective than the Heimlich manoeuvre for treating complete airway obstruction by a foreign body.

Acknowledgements

This study was supported by a grant from the Norwegian Air Ambulance. The authors would like to thank the paramedics in the Oslo Ambulance Service for valuable participation and Andreas Skulberg for his input.

References

[1] Statistisk sentralbyrå. Causes of Death 1995. Oslo: Statistisk sentralbyrå, 1998.

[2] Accident Facts. 1984 Edition. National Safety Council. Chicago, 1984.

[3] Handley AJ, Bahr J, Baskett P, Bossaert L, Chamberlain D, Dick W, Ekstrom L, Juchems R, Kettler D, Marsden A, et al. The European Resuscitation Council guidelines for adult single rescuer basic life support: a statement from the Working Group on Basic Life Support, and approved by the executive committee (see comments).

Resuscitation 1998;37(2):67–80 published erratum appears in Resuscitation 1998 Aug; 38 (2): 131–2.

[4] American Heart Association. Guidelines for cardiopulmonary resuscitation and emergency cardiac care. J Am Med Assoc 1992;268:2191–4.

[5] Day RL, Crelin ES, DuBois AB. Choking: the Heimlich abdominal thrust vs back blows: an approach to measurement of inertial and aerodynamic forces. Pediatrics 1982;70(1):113–9.

[6] Heimlich HJ. A life-saving maneuver to prevent food-choking. J Am Med Assoc 1975;234:398–401.

[7] Skulberg A. Chest compression — an alternative to the Heimlich manoeuvre? (letter). Resuscitation 1992;24:91.

[8] Gordon AS, Belton MK, Ridolpho PF, Safar P, Elam J. Emergency management of foreign body airway obstruction. In: Advances in Cardiopulmonary Resuscitation. New York: Springer, 1977:39.

[9] Guildner CW, Williams D, Subitch T. Airway obstructed by foreign material: the Heimlich manoeuvre, JACEP 1976;5:675–7.

[10] Ruben H, Macnaughton FI. The treatment of food-choking. Practitioner 1978;221:725–9.

[11] Heimlich HJ, Patrick EA. The Heimlich maneuver: best technique for saving any choking victim's life (see comments). Postgrad Med 1990;87, 53:38–43.

[12] Weaver FJ, Ramirez AG, Dorfman SB, Raizner AE. Trainees' retention of cardiopulmonary resuscitation:how quickly they forgot. J Am Med Assoc 1970;241:901–3.

[13] Bjorshol CA. Cardiopulmonary resuscitation skills: a survey among health and rescue personnel outside hospital (in Norwegian). Tidsskr Nor Laegeforen 1996;116:508–11.

[14] Kaye W, Mancini ME. Retention of cardiopulmonary resuscitation skills by physicians, registered nurses, and the general public. Crit Care Med 1986;14:620–2.

[15] Eisenburger P, Safar P. Life supporting first aid training of the public — review and recommendations. Resuscitation 1999;41:3–18.

ELSEVIER

Resuscitation 48 (2001) 185–188

RESUSCITATION

www.elsevier.com/locate/resuscitation

Letters to the Editor

Langhelle et al. (Resuscitation 2000;44:105-108), using cadavers, found chest compressions yielded higher airway pressures than Heimlich maneuvers when the airway was obstructed. They conclude one should use chest compressions rather than Heimlich maneuvers to expel a foreign body from the airway. That recommendation is an error similar to one made by Guildner 25 years ago [1] when the Maneuver was first discovered. The correct method must be based on physics, not speculation.

The facts are as follows:

1. Patrick, a physician and engineering professor at Purdue University, pointed out the well-established scientific fact that the transmission of energy is related to the duration of pressure. A spike of pressure provides negligible kinetic energy to the obstructing object [2]. Patrick demonstrated it is the flow of air from the lungs toward the mouth, resulting from the Heimlich maneuver that transmits kinetic energy to a foreign body sufficient to carry it out of the airway and mouth [3]. The Heimlich maneuver consists of pressing the diaphragm upward, which diminishes the volume of the chest cavity, and compresses the lungs uniformly, thus producing a flow of 940 cm^3 of air in 1/4 s (a flow rate of 205 l/min) [4]. That is why the maneuver has successfully saved the lives of tens of thousands of people throughout the world.
2. The effectiveness of the Heimlich maneuver to produce a significant flow is also proven when the Maneuver is used to expel water from the lungs of drowning victims. A 1982 University of Pittsburgh study showed four Heimlich maneuvers yield a flow of water sufficient to clear the water from the lungs [5].
3. One important issue, which was not studied in the Langhelle paper, is the question of iatrogenic injuries. Serious complications have been reported with great frequency, resulting from CPR [6–8]. The 1992 American Heart Association *Guidelines for Cardiopulmonary Resuscitation and Emergency Cardiac Care* warn, 'Even properly performed chest compressions can cause rib fractures in some patients. Other complications may occur despite proper CPR technique, including fracture of the sternum, separation of the ribs from the sternum, pneurnothorax, lung contusions, lacerations of the livers and spleen, and fat emboli' [9]. In contrast, in 1985, United States Surgeon General C. Everett Koop declared. 'The Heimlich Maneuver is safe, effective and easily mastered by the average person. It can be performed on standing or seated victims and on persons who have fallen to the floor. It can be performed on children and even on one's self' [10].
4. Langhelle et al. accurately state, 'There is much evidence in the literature that the learning and retention of CPR skills is not very efficient,' but suggest CPR, without the Heimlich maneuver, will simplify the protocol for choking. In actuality, CPR is rarely needed after the Heimlich maneuver removes the choking object. Most importantly, adults and children have learned the Heimlich maneuver, and saved lives, having seen a 30-s public service announcement on television.

The Langhelle article repeatedly uses the term 'abdominal thrusts'. In his 1985 declaration, Surgeon General Koop says, '... these methods are hazardous, even lethal. Chest and abdominal thrusts, because they refer to blows to unspecified locations on the body, have resulted in cracked ribs and damaged spleens and livers, among other injuries' [10]. The correct technical description of the Heimlich maneuver is 'subdiaphragmatic pressure'.

The 1992 American Heart Association *Guidelines* [9] recommend 'that the chest thrusts be used in the markedly obese person...' presumably be-

cause the rescuer cannot reach around the victim. Langhelle notes, however, that with the rescuer astride the corpulent person in the supine position, as used for unconscious victims, that the Heimlich maneuver may be used successfully, which is a significant finding.

Langhelle's speculative recommendations can be reconsidered should new evidence indicate it is warranted.

References

[1] Guildner CW, Williams D, Subitch T. Airway obstructed by foreign material: the Heimlich maneuver. JACEP 1976;5:675–77.
[2] Day RL, Crelin ES, DuBois AB. Choking: the Heimlich abdominal thrust versus back blows: an approach to measurement of inertial and aerodynamic forces. Pediatrics 1982;70:113–9.
[3] Heimlich HJ, Patrick EA. The Heimlich maneuver: best technique for saving any choking victim's life. Postgrad Med 1990;87(6):38–48,53.
[4] Heimlich HJ, Hoffmann KA, Canestri FR. Food-choking and drowning deaths prevented by external subdiaphragmatic compression. Ann Thorac Surg 1975;20:188–95.
[5] Werner JZ, Safar P, Bircher NG, Stezoski W, Scanlon M, Stewart RD. No improvement in pulmonary status by gravity drainage or abdominal thrusts after sea water near drowning in dogs. Anaesthesiology 1982;57 (suppl. 3A):A81.
[6] Paaske F, Hart Hansen JP, Koudahl G, Olsen J. Complications of closed-chest cardiac massage in a forensic autopsy material. Dan Med Bull 1968;15:225–30.
[7] Atcheson SG, Fred HL. Complications of cardiac resuscitation. Am Heart J 1975;89:263–65.
[8] Fletter B, Jones J. Complications after cardiopulmonary resuscitation. Am J Emerg Med 1994;12:687–88.
[9] Emergency Cardiac Care Committee and Subcommittees, American Heart Association. Guidelines for cardiopulmonary resuscitation and emergency cardiac care. Adult basic life support. J Am Med Assoc 1992;268:2184–98.
[10] Koop CE. The Heimlich Maneuver. Pub Health Rep 1985;100:557.

Henry J. Heimlich,
Eric G Spletzer
2 The Heimlich Institute,
311 Straight Street,
Cincinnati,
OH 45219,
USA

PII: S0300-9572(00)00333-6

Response to Heimlich and Spletzer

We want to thank Dr Heimlich and Dr Spletser for this opportunity to discuss further the removal of a foreign body from the airway. The science pertaining to this technique was thoroughly reviewed in the recent international guidelines process [1]. We do not recollect that one group of papers was seen as more speculative than others, thus, we forego a thorough discussion of speculation versus science. As stated in the guidelines, "The level of evidence regarding any of these methods is weak, largely contained in case reports, cadaver studies, small studies involving animals or mechanical models" [1].

In our article, the potential importance of a maintained pressure over time is discussed, including the point that pressure will be maintained for a longer period with chest compressions than precordial thumps, and longest if the chest compressions have the recommended square wave form. We now speculate that chest thrusts and backslaps will come into the same category as precordial thumps. While we agree that the duration of the applied pressure is potentially important, we are unaware of strong human evidence for this. Foreign bodies have also been removed by backslaps. It is interesting to note that Ruben and MacNaughton [2] found that a pressure of 70 m^3 H_2O applied in a series of impulses could eject a piece of raw beef, while a steady pressure of up to 100 m^3 H_2O was ineffective. As referred to in our article, Gordon et al. [3] reported similar airflows with the Heimlich manoeuvre and chest compressions. We are a little uncertain why Heimlich and Spletser refers to Guildner et al. [4] who measured both pressure and air-flows in humans as speculative, as this is in contrast to other scientists who recommend Heimlich manoeuvre. We also find it difficult to discard Ruben and MacNaughton [2] who also find better results with other techniques than the Heimlich manoeuvre in humans.

It was further of interest that in two cadavers in our study, the Heimlich manoeuvre gave no change in airway pressure, while the pressure increased in both with chest compressions. This cannot be explained by a poorly performed Heimlich manoeuvre, as it was done by a physician with 25 years experience in in- and out-of-hospital emergency medicine, which included the removal of foreign bodies (both by the Heimlich man-

oeuvre and backslaps). However, as long as an airway pressure of zero is upheld, a foreign body is not likely to be expelled based on physical principles. It is fascinating that Heimlich and Spletser refers to our one corpulent patient who had a higher pressure generated with the Heimlich manoeuvre as significant, while the rest of our discussion apparently is based on speculation.

While it is true that complications can occur with chest compressions, the most dreaded complications can occur if the pressure applied is too low, viz. damage to abdominal organs. More importantly, it should be noted that the pulse check during basic life support has been de-emphasised or removed [1]. The sensitivity and specificity of the pulse check is too low. Thus, if a patient is unconscious and not breathing normally, full CPR should be started if there are no other signs of a circulation. This is important whether there is a foreign body obstruction or not.

We have no problems with the term 'subdiaphragmatic pressure'.

References

[1] Adult basic life support. International Guidelines. Resuscitation 2000;46(1–3):29–71.
[2] Ruben H, Macnaughton FI. The treatment of food-choking. Practitioner 1978;221:725–9.
[3] Gordon AS, Belton MK, Ridolpho PF, Safar P, Elam J. Emergency management of foreign body airway obstruction. In: Advances in Cardiopulmonary Resuscitation. New York: Springer, 1977:39.
[4] Guildner CW, Williams D, Subitch T. Airway obstructed by foreign material: the Heimlich maneuver. JACEP 1976;5:675–7.

Petter Andreas Steen[a,c], Audun Langhelle[a], Lars Wik[b], Kjetil Sunde[c]
[a] *University of Oslo Oslo, Norway*
[b] *Medinnova Science Foundation, Oslo, Norway*
[c] *Department of Anaesthesiology Ullevaal University Hospital, 0407 Oslo, Norway*
E-mail: p.a.steen@ioks.no

PII: S0300-9572(00)00332-4

On the existence of dragons

We were very interested to note the recent correspondence between Dr Steen and Dr Oxer [1] on the subject of proving/not proving the existence of oxygen toxicity in resuscitation and first aid. Zwemer et al. [2,3] have published two articles in 'Resuscitation' on the subject. In these experimental works, he has demonstrated that 100% oxygen during experimental CPR leads to worse neurological outcome and periodic hypoxic ventilation during experimental CPR has no benefit compared to air ventilation. Liu et al. [4] has also contributed with similar data from a canine model, where less oxidation of brain lipids occurred when normoxia was used instead of hyperoxia. For some time there has been a discussion on the possible effects of oxygen free radicals, but there have been difficulties in determining the precise role of these radicals. Recently, however, our group [5] has published data unequivocally demonstrating the increased effects of oxygen free radicals during reperfusion after experimental CPR, by demonstrating an increased plasma level of the isoprostane 8-iso-prostaglandin $F_{2\alpha}$ This isoprostane has been validated as a highly sensitive and specific biomarker of in vivo non-enzymatic lipid peroxidation. The fact that the level of 8-iso-prostaglandin $F_{2\alpha}$ was highest in the plasma seems to provide the ill effects of oxygen in the brain during reperfusion. So now there is experimental evidence suggesting that oxygen toxicity/dragons does occur during reperfusion after resuscitation and first aid, rather than the opposite.

References

[1] Oxer HF. Simply add oxygen. Why isn't oxygen administration taught in all resuscitation training? Resuscitation 2000;43:163–9.
[2] Zwemer CF, Whitesall SE, D'Alecy LG. Cardiopulmonary-cerebral resuscitation with 100% oxygen exacerbates neurological dysfunction following nine minutes of normothermic cardiac arrest in dogs. Resuscitation 1994;27(2):159–70.
[3] Zwerner CF, Whitesall SE, D'Alecy LG. Hypoxic cardiopulmonary-cerebral resuscitation fails to improve neurological outcome following cardiac arrest in dogs. Resuscitation 1995;29(3):225–36.